

## Bones of the foot

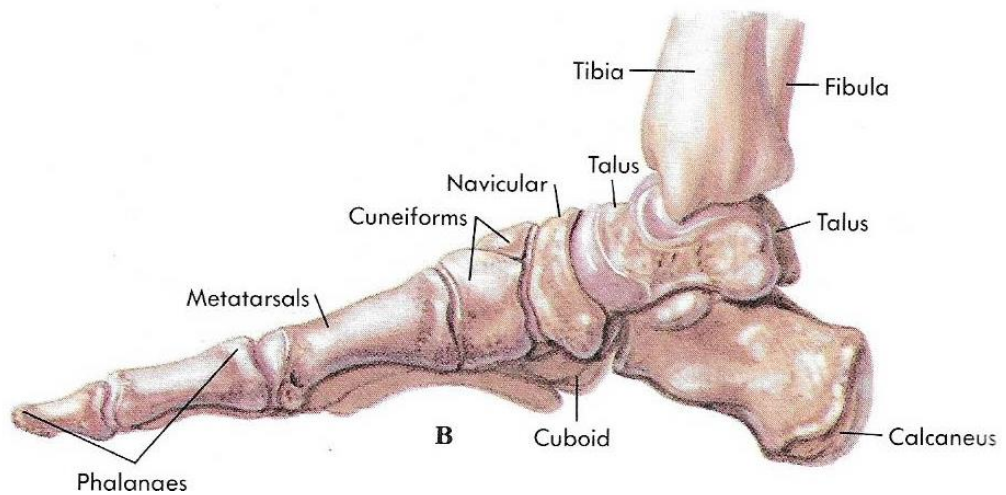
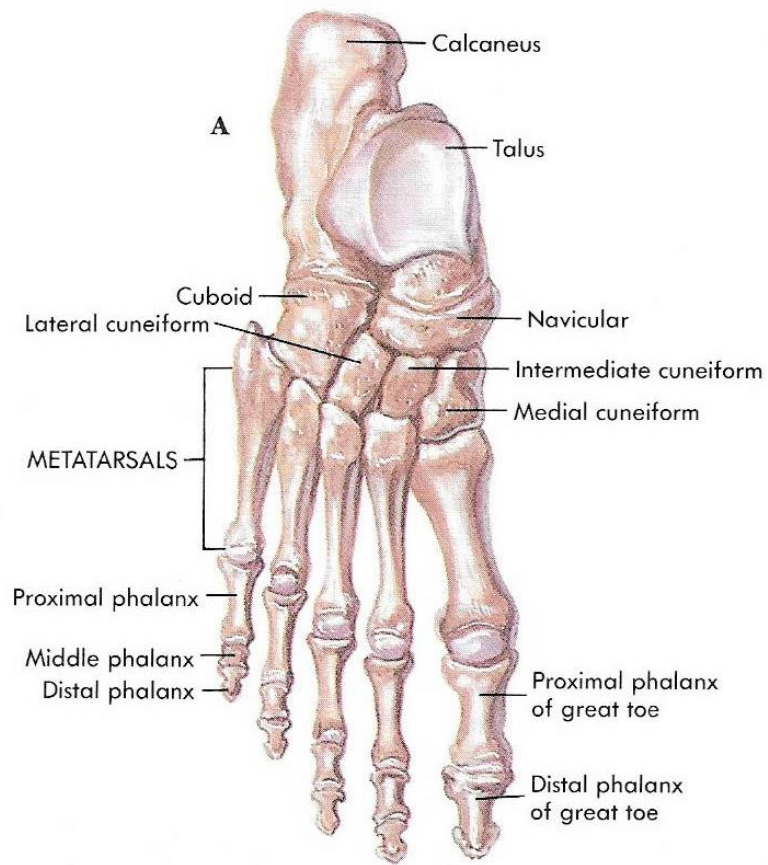


Image ref: Anatomy & Physiology, Seeley Stephens Tate 1989